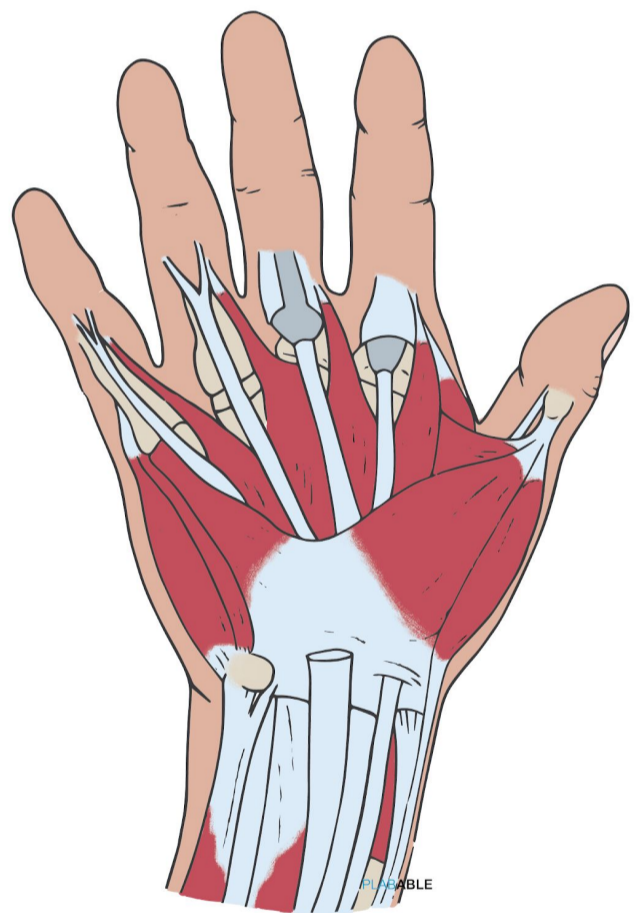
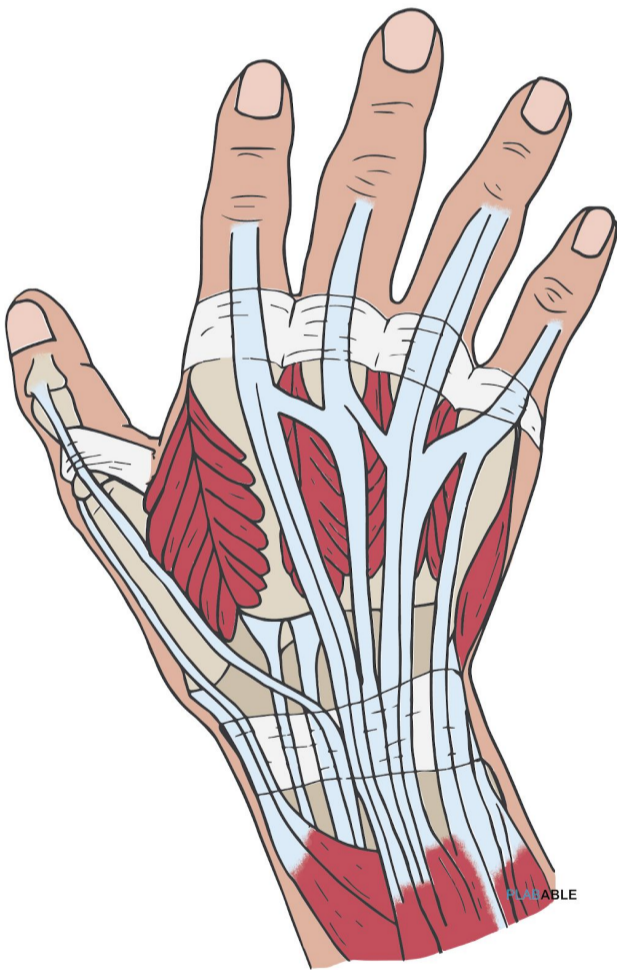


PLABABLE

GEMS 

VERSION 1.2

ANATOMY



Anatomical Landmarks

C 6-7	Stellate ganglion
T5-8	Heart position
5th intercostal space	Apex of heart (Midclavicular line)
5th intercostal space	Mid axillary line Drain position for pleural tap
9th costal cartilage	Gallbladder fundus
T3-4	Manubrium
T10	Xiphoid process
T12-L3	Kidney position
L1	Transpyloric plane
L2	Subcostal plane
L4	Iliac crest
L5	Intertubercular plane
S2	ASIS, PSIS

Anatomical Landmarks

Diaphragmatic Openings: **VOA !!**

- **V** → (Inferior) Vena cava : T8
- **O** → Oesophagus : T10
- **A** → Aorta : T12

Umbilicus L 3-4

Scapula

- Spine → T3
- Inferior angle → T7 Spinous process

Spinal cord

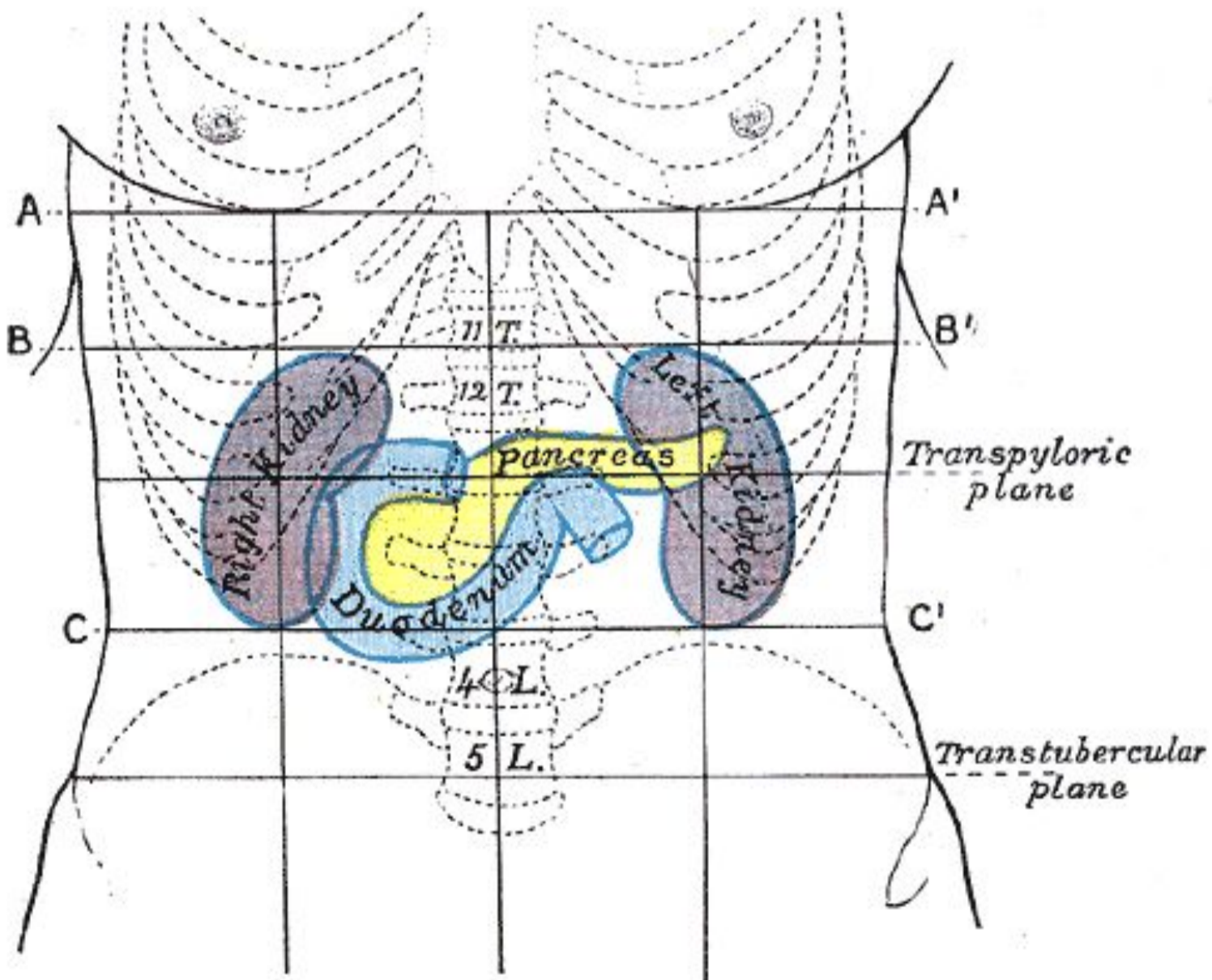
Extend to

- Lower border of L1 : Adults
- Lower/upper border of L3 : Children

Anatomical Landmarks

L1

- Transpyloric plane
- Gallbladder fundus
- Coeliac trunk
- Superior mesenteric artery
- Termination of spinal cord in adults
- Hilum of kidney



Nerve injury pointers

Upper limb

Wrist drop	Radial nerve
Claw hand	Ulnar nerve
Paresthesia ring + little finger	Ulnar nerve
Paresthesia middle + index + thumb	Median
Humeral neck #	Axillary nerve
Humeral shaft #	Radial nerve
Supracondylar #	Median nerve (Anterior interosseous nerve branch)
Saturday night palsy Crutch palsy	Radial nerve
Winging of scapula	Long thoracic nerve
Dropped scapula	Accessory nerve

Long thoracic nerve

Brain trainer:

A young man presents with increased scapula winging when doing a push-up against the wall and pain induced on contralateral tilting of the head. What is the most likely diagnosis?

→ **Long thoracic nerve**

Saphenous nerve

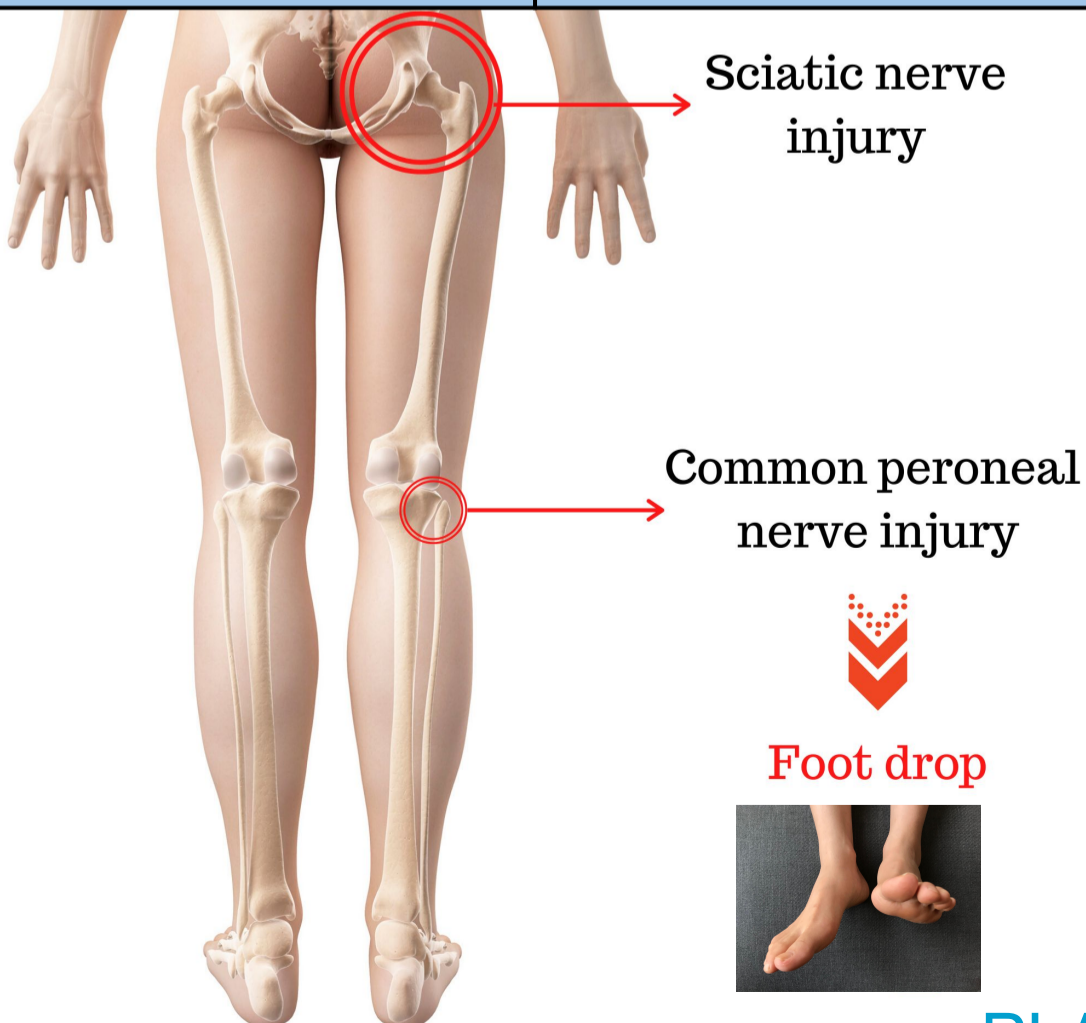
Brain trainer:

After surgery for varicose veins a patient complains of numbness on the medial side of his foot. What is the SINGLE most likely nerve involved?

→ **Saphenous nerve**

Nerve injury pointers - lower limb

Femur neck # Acetabular #	Sciatic nerve
Neck of fibula #	Common peroneal nerve
Foot drop	Sciatic / Common & Deep peroneal nerve
Loss of sensation medial side foot	Saphenous nerve
Loss of sensation lateral side foot	Sural nerve
Glove and stocking pattern of paresthesia	Diabetes melitus



Brachial plexus injury

Brain trainer:

A man presents with reduced sensation on the medial and posterior aspect of his lower left forearm running down to his little finger, weakness of thumb extension, wrist ulnar deviation and wasting of the muscles of the left hand. What is the most likely affected structure?

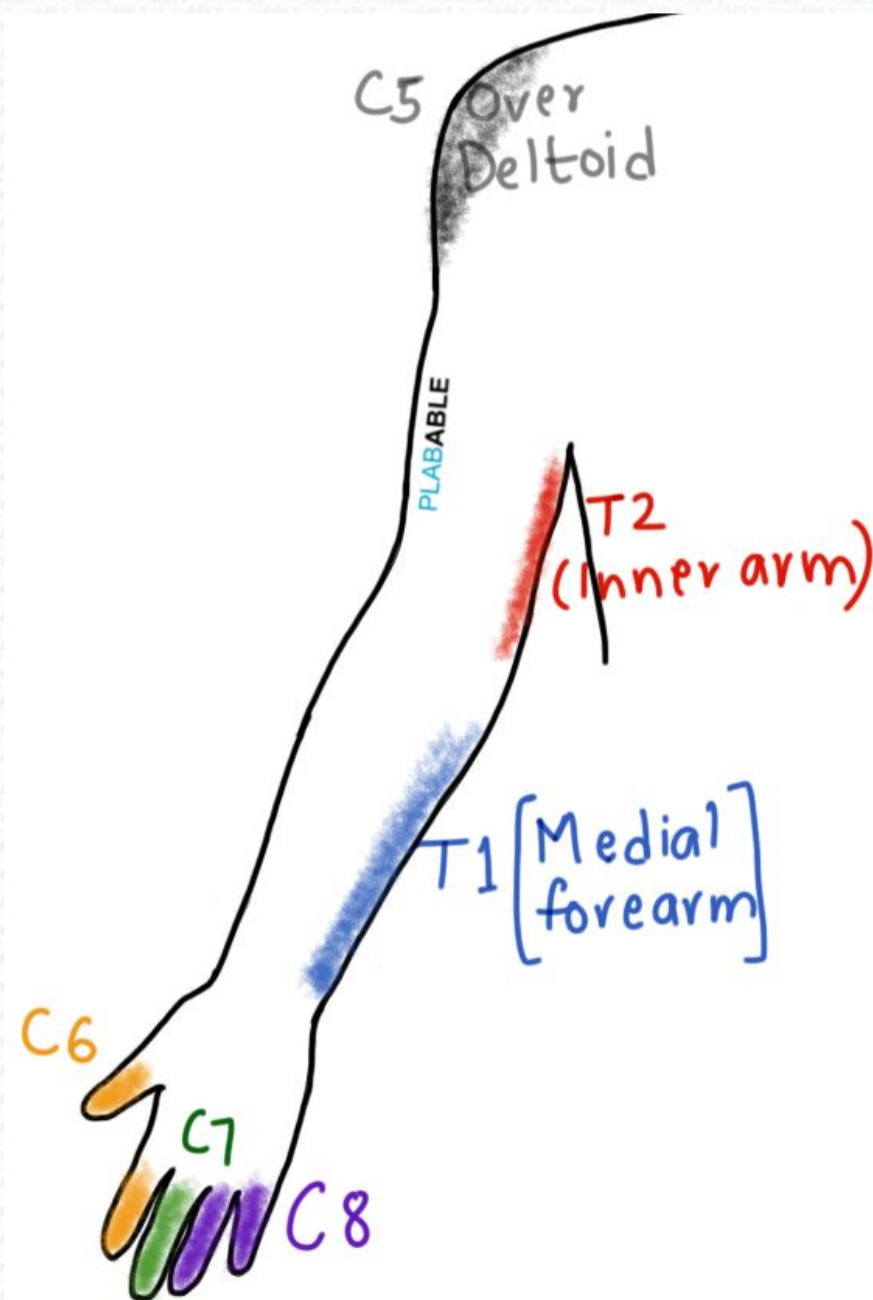
→ **C8 nerve root**

Brachial plexus injury

Motor distribution:

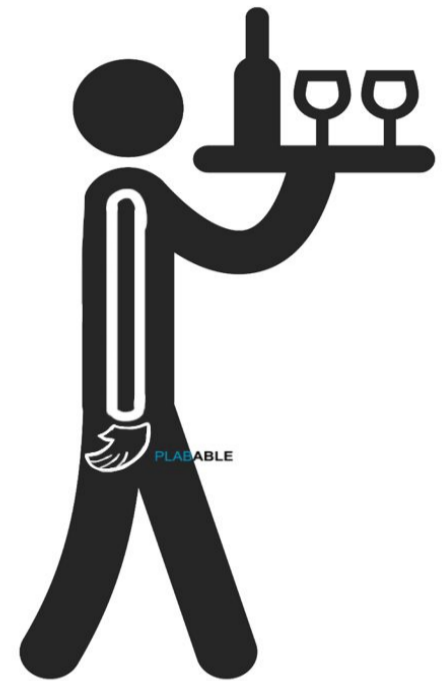
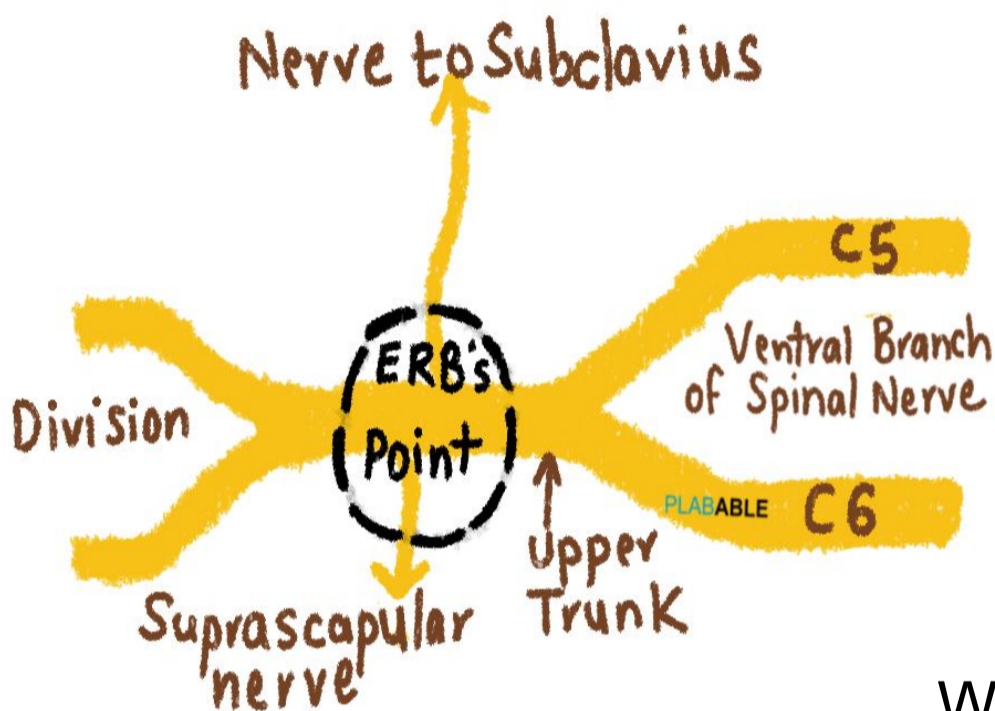
Root value	Gross motor function
C5,6	Shoulder abduction Elbow flexion
C7	Triceps +/- Wrist extension
C8 T1	Hand function

Sensory distribution



Erb's palsy

Injury to upper brachial plexus: **C5-C6 roots**
Sometimes C7 root can also be involved



Waiter's tip deformity

- Lateral traction to upper limb
- Common birth injury with **shoulder dystocia**
- Accidental with injury to neck (**motorbike accidents**)

Actions affected

- Shoulder abduction + Elbow flexion
- Triceps + Wrist extension if, C7 is involved

Arm: Abducted and internally rotated

Forearm: Extension and supination

(+/- Wrist in flexion)

Waiter's tip deformity

Klumpke's palsy

Injury to lower brachial plexus: **C8-T1 roots**

- Upward force (pulling) to upper limb
- Vaginal birth injury
- Accidental with injury to neck (**motorbike accidents**)

Muscles affected

- Muscles of hand: **Intrinsic + Thenar + Hypothenar**
- Forearm pronators + Wrist flexors can be involved
- May be associated with **Horner's syndrome** (meiosis+ptosis) with T1 involvement

Deformity

- Claw hand
- Forearm supinated
- Wrist extended

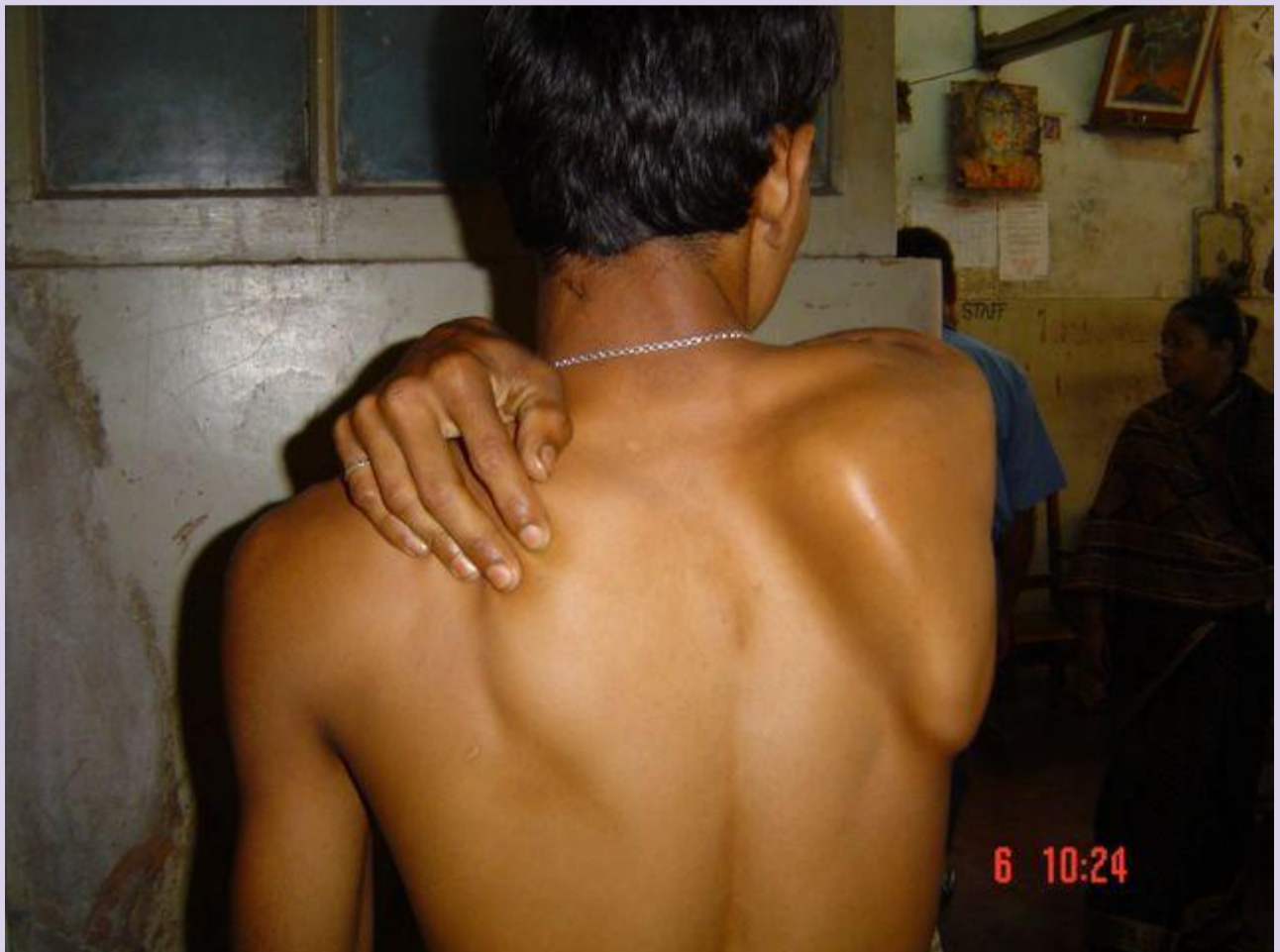

Long thoracic nerve (C5,6,7) → Winging of scapula

Winging of scapula

Injury to Long thoracic nerve **C5,6,7 roots**

Weakness of serratus anterior muscle



It can also occur due to atrophy of trapezius due to injury to Spinal accessory nerve.

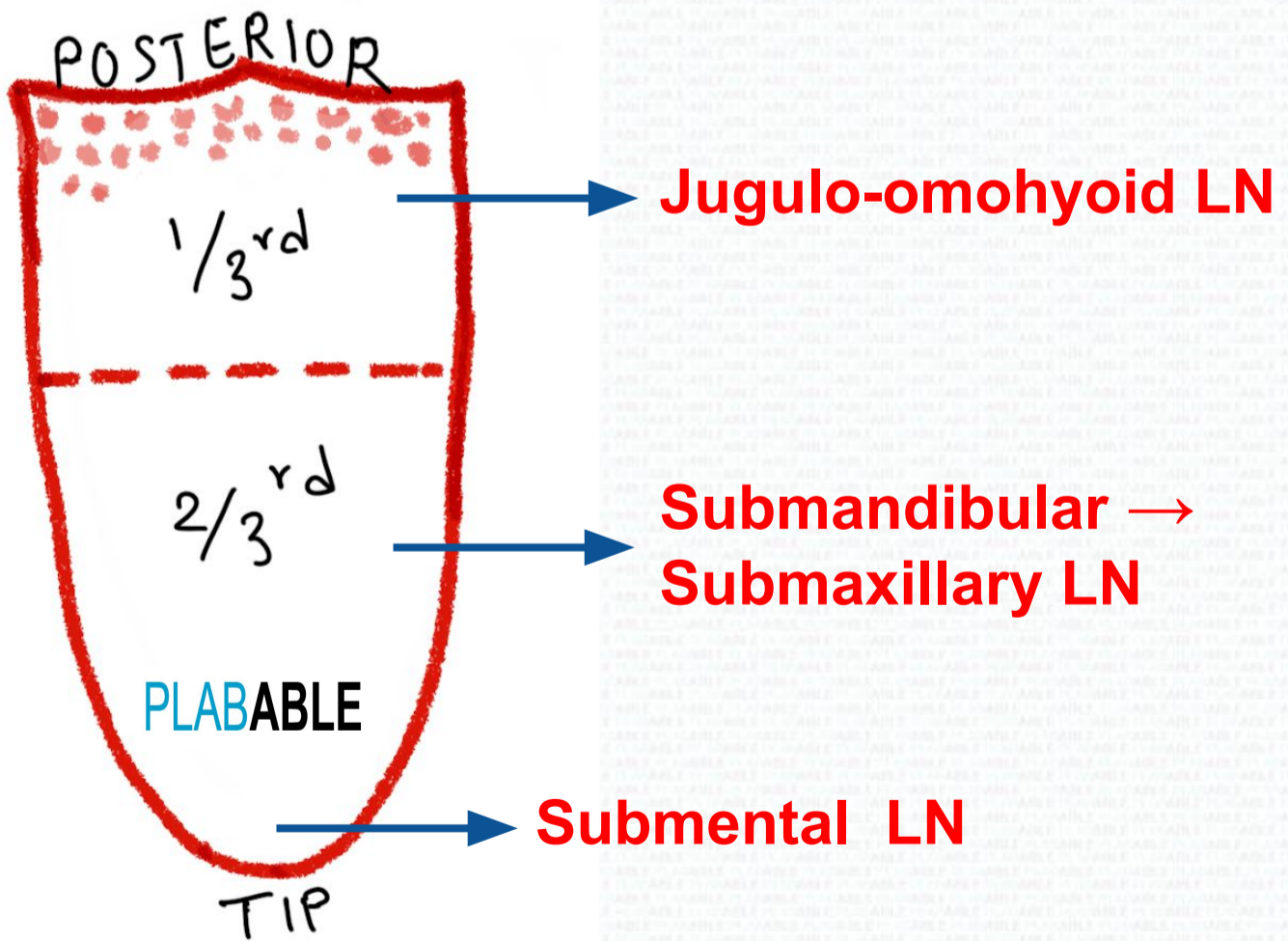
Causes

- Traumatic
- Repetitive injury

Lymphatic drainage

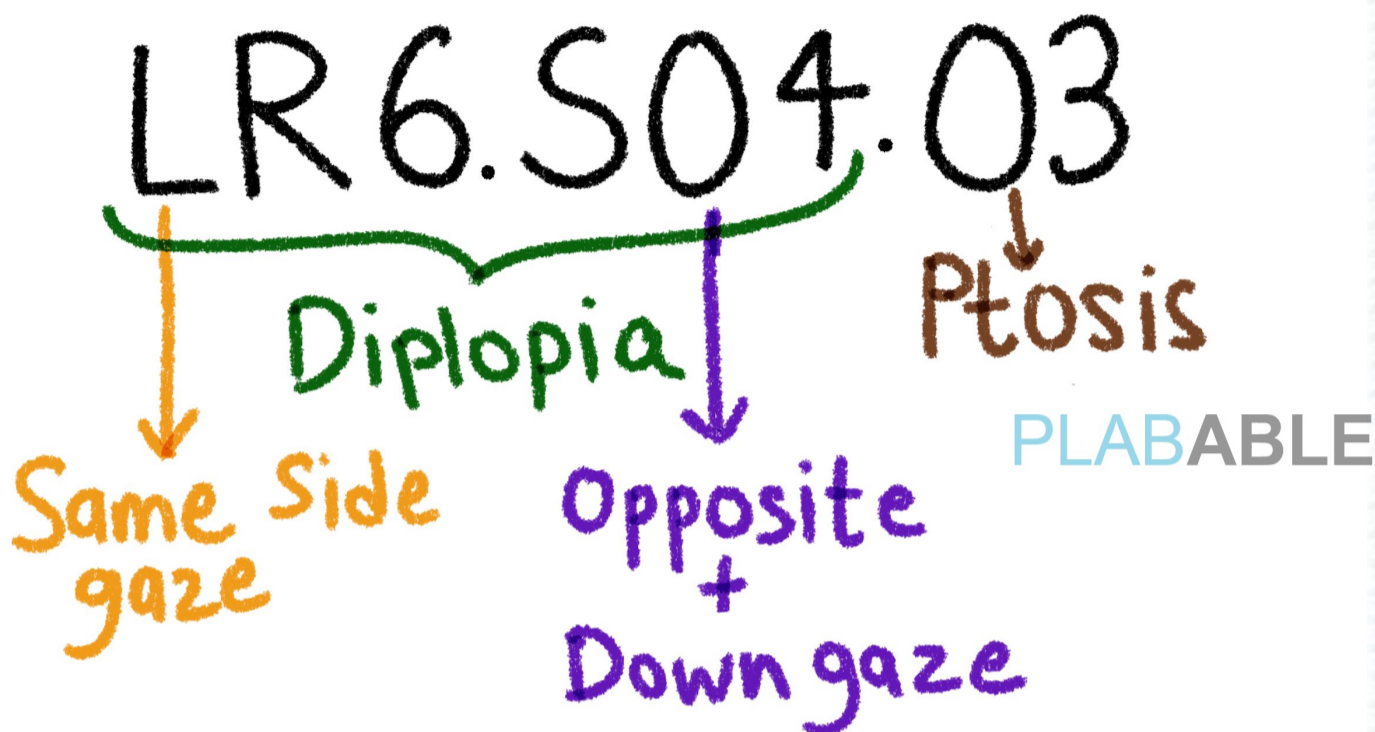
- **Ovary & Testis** : Para-aortic lymph nodes
- **Scrotum & Vulva** : Superficial inguinal LN
- **Posterior oropharynx** : Deep cervical → Jugular
- **Medial malleolus** : Inguinal LN
- **Lateral malleolus** : Popliteal → Inguinal

Tongue



Nerves involving eye clinchers

Important keywords to look for in the question



CN 6 : Abducens nerve → Lateral rectus

Injury causes **diplopia** on looking towards **same side**

eg. Nerve lesion in **left eye** will cause diplopia on looking towards **left side**

CN 4 : Trochlear nerve → Superior rectus

Injury causes **diplopia** on looking opposite side and downward direction

CN 3 : Oculomotor nerve → Other eye muscles

Injury causes ptosis along with **mydriasis**

Double vision

Brain trainer:

A boy sees double vision when walking down stairs and when he looks to the right. What nerve is affected?

→ **Left Trochlear nerve**

Visual defect

Brain trainer:

An elderly man with a history of stroke has long term memory impairment, altered sexual behaviour and a visual defect. What is the most likely visual defect?

→ **Upper homonymous quadrantanopias**

The temporal lobe is affected in this case.

Biliary colic

Brain trainer:

An ERCP shows a calculus lodged in the second part of the duodenum. What is the SINGLE most likely place that the stone was lodged?

→ **Hepatopancreatic ampulla**

This structure is also known as “Ampulla of Vater”

Deep Fibular nerve

Brain trainer:

A man sat cross-legged for 30 minutes after which he found himself unable to dorsiflex his left foot and had loss of sensation in the web space between the big toe and the second toe. What nerve is affected?

→ **Deep peroneal nerve**

Herpes zoster

Brain trainer:

A man has herpes zoster over the dermatome of the maxillary branch of the trigeminal nerve. Which type of mucosa will be affected?

→ **Palate**

Lymph node

Brain trainer:

A man has a non healing ulcer on the skin of the right medial malleolus. Which lymph node is likely to be involved?

→ Inguinal lymph node

Rheumatoid arthritis

Brain trainer:

An elderly woman with rheumatoid arthritis is unable to extend the fingers of her right hand at the metacarpophalangeal joint and interphalangeal joints following a fall. What is the most likely damaged tendon?

→ **Extensor digitorum**

Fractured radius

Brain trainer:

After fracturing her radius a woman presents with the inability to extend her thumb at the interphalangeal joint. Which tendon is damaged??

→ **Extensor Pollicis Longus**

Hand injury

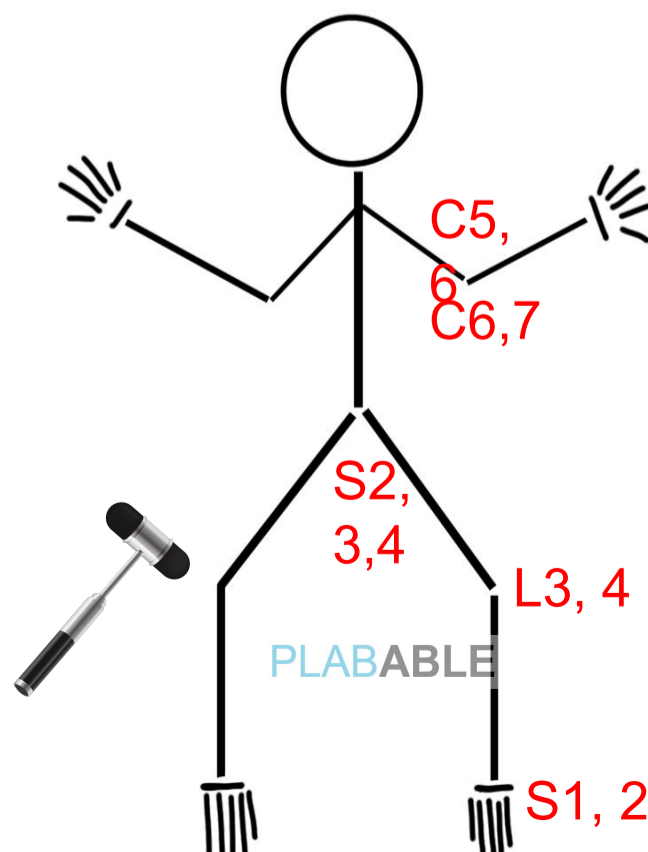
Brain trainer:

A man struck his hand against a door. On examination, he could extend the interphalangeal joint of his right thumb but the metacarpophalangeal joint of the thumb remained flex. What tendon is damaged?

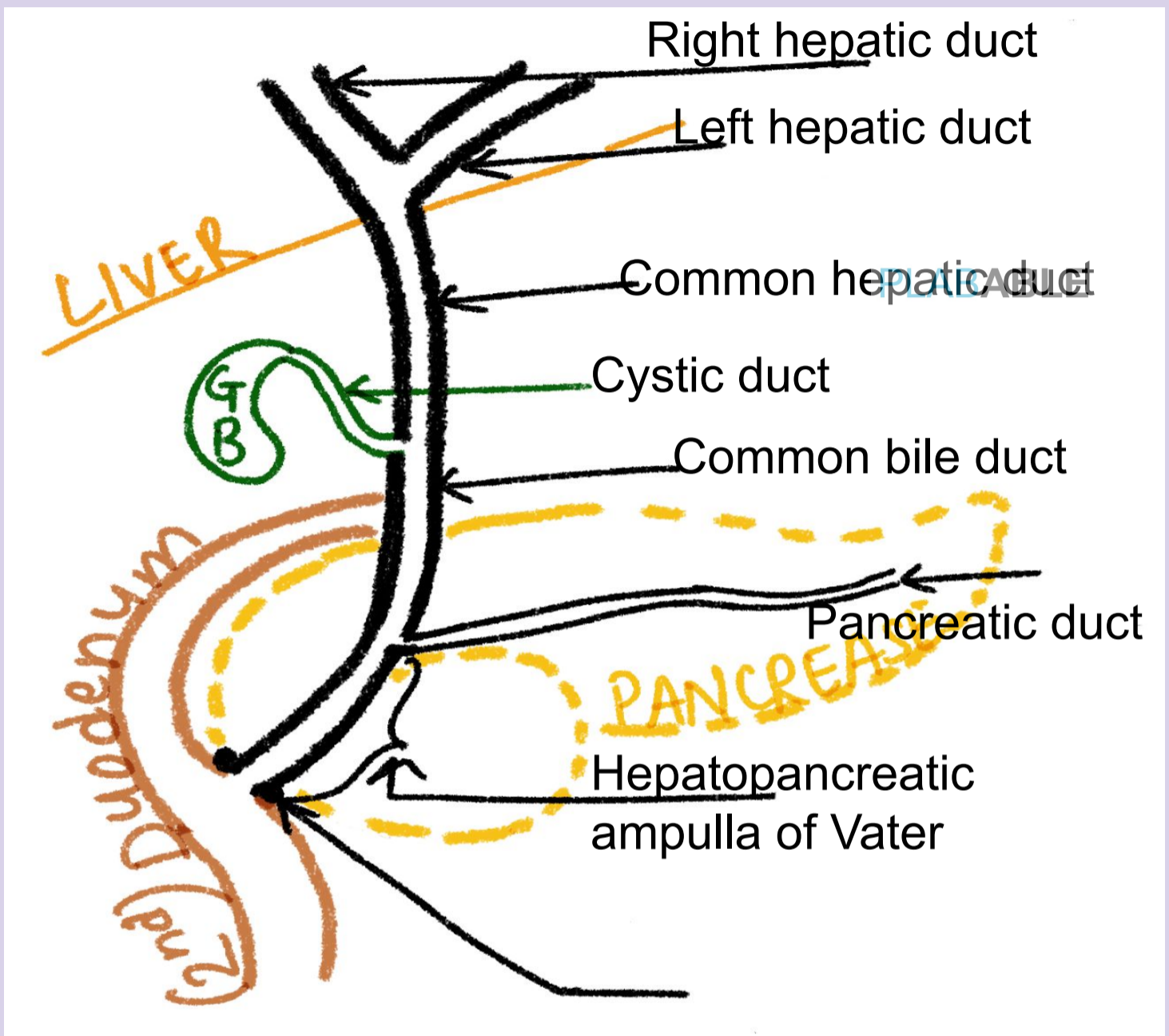
→ **Extensor Pollicis Brevis**

Reflexes

Reflex	Root value
Biceps	C5,6
Brachioradialis	C6,7
Triceps	C6,7
Knee	L3,4
Ankle	S1,2
Anal	S2,3,4



Hepatobiliary system



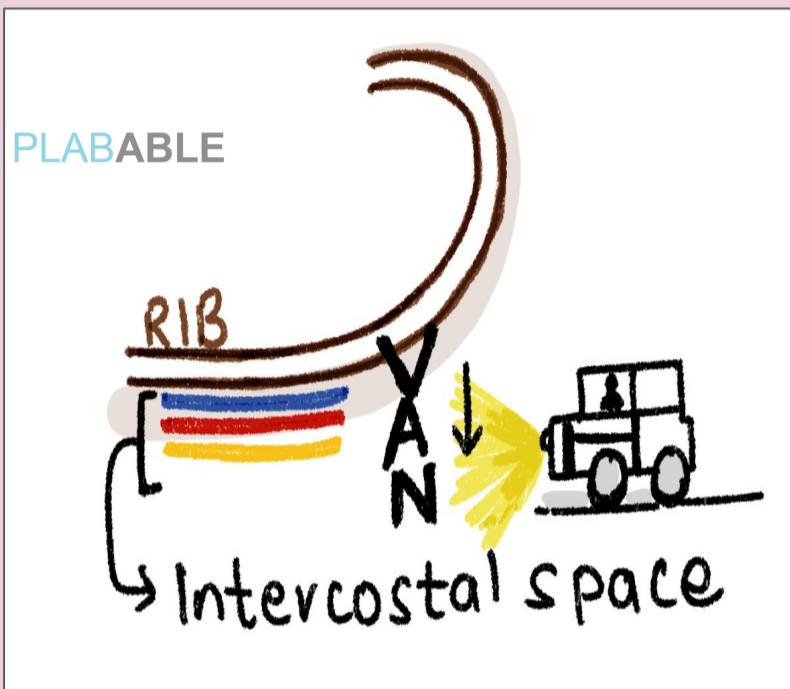Biliary colic → When stone occluded cystic duct

- Colicky pain in right upper quadrant
- Radiating to right shoulder or interscapular region

ERCP → Endoscopic Retrograde
Cholangiopancreatography

To visualise and treat problems of bile duct and
pancreatic duct

Placement of drain

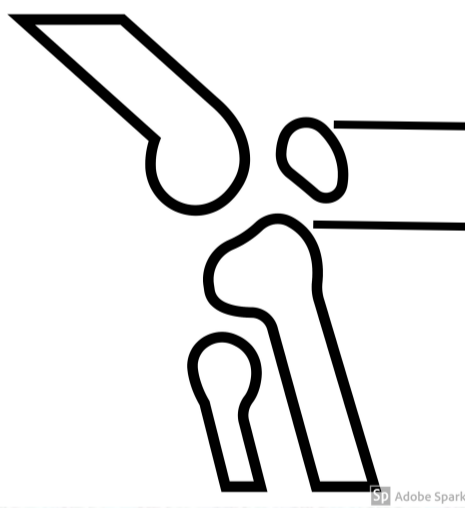


- 5th intercostal space
- Mid axillary line

Place at the superior border of rib to avoid injury to VAN

Knee bursa

Prepatellar bursitis → Housemaid's knee
Infrapatellar bursitis → Clergyman's knee
(Clergymen sit down and pray: infrapatellar)



Prepatellar bursa

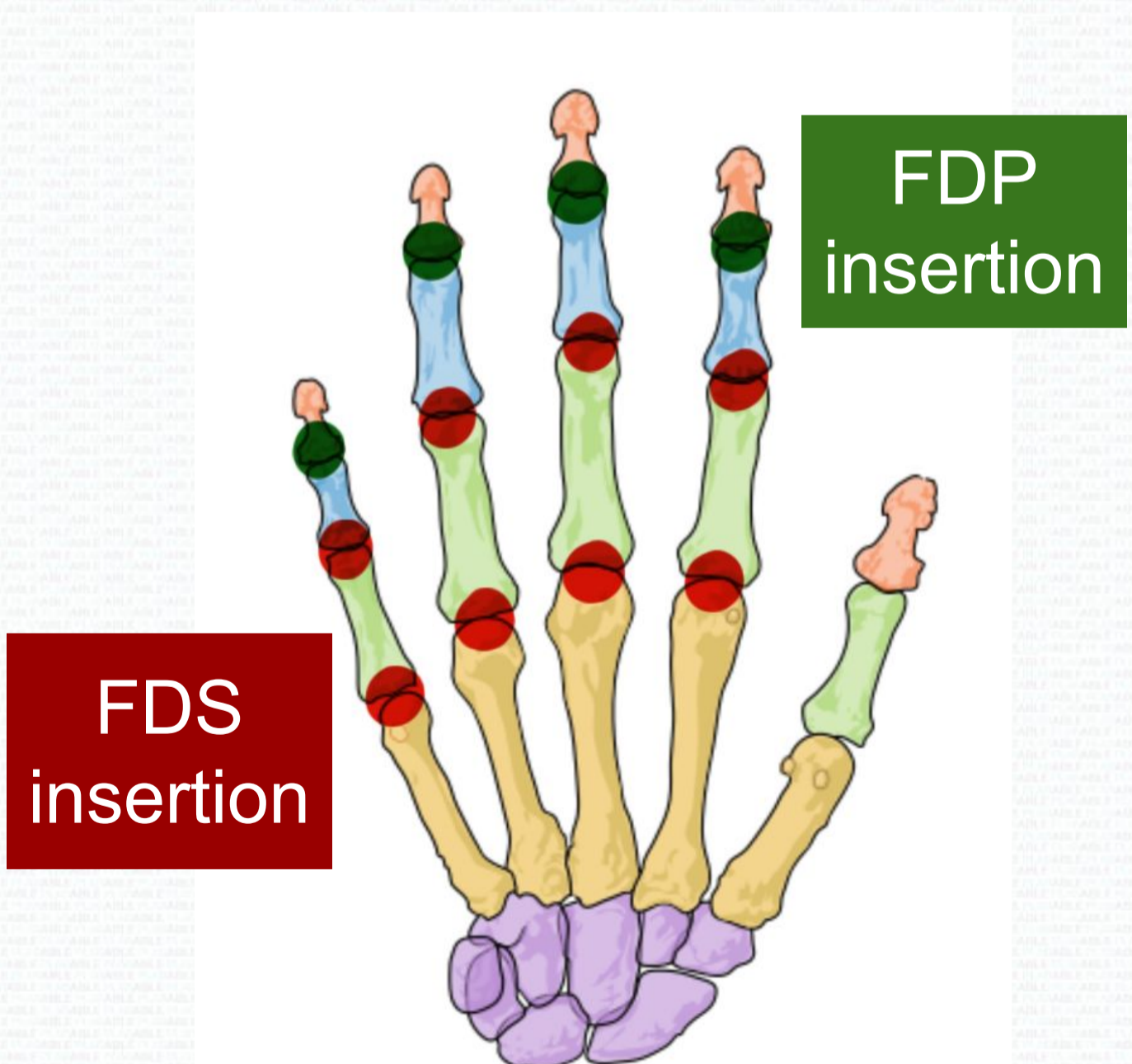
Infrapatellar bursa

Muscles the of hand

- **Flexor digitorum superficialis : MCP + PIP**
- **Flexor digitorum profundus : DIP**

Note: Superficialis is a superficial muscle; hence it crosses **only proximal joints** of MCP & PIP

Profundus is a deeper and **longer** muscle hence it crosses **distal joint** of DIP

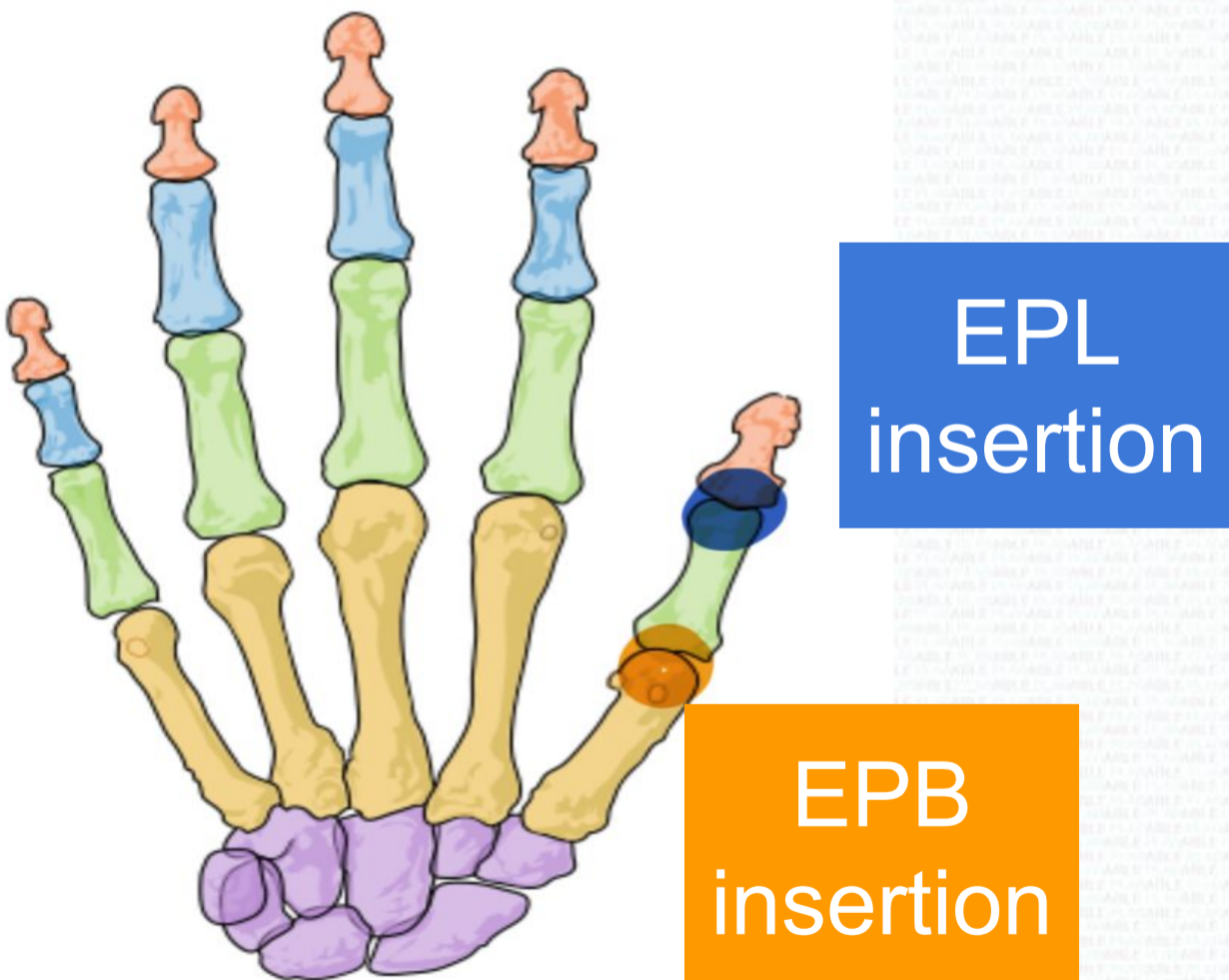


Muscles of the hand

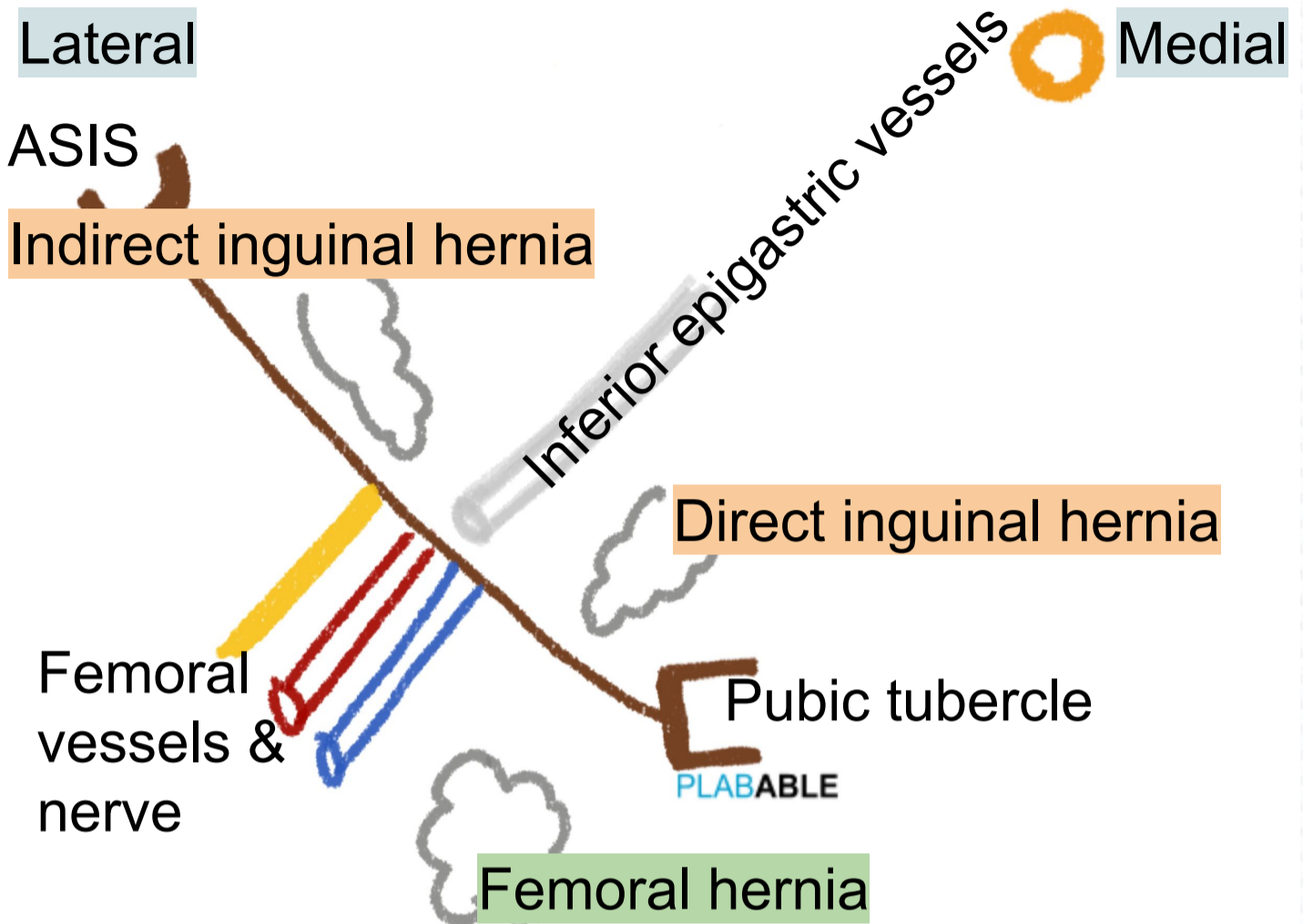
Extensor digitorum communis → Extend hands, wrist, fingers

Extensor pollicis brevis → MCP of thumb (brevis means shorter so, nearer joint which is MCP)

Extensor pollicis longus → IP of thumb (longer means it crosses a joint which is farther ie IP)



Hernia anatomy



- Direct inguinal hernia is medial to inferior epigastric vessels
- Femoral artery is lateral to femoral hernia
- Deep inguinal ring one inch above midpoint of inguinal ligament

Mid Inguinal point → Halfway between pubic symphysis and ASIS

Midpoint of inguinal ligament → halfway between pubic tubercle and ASIS

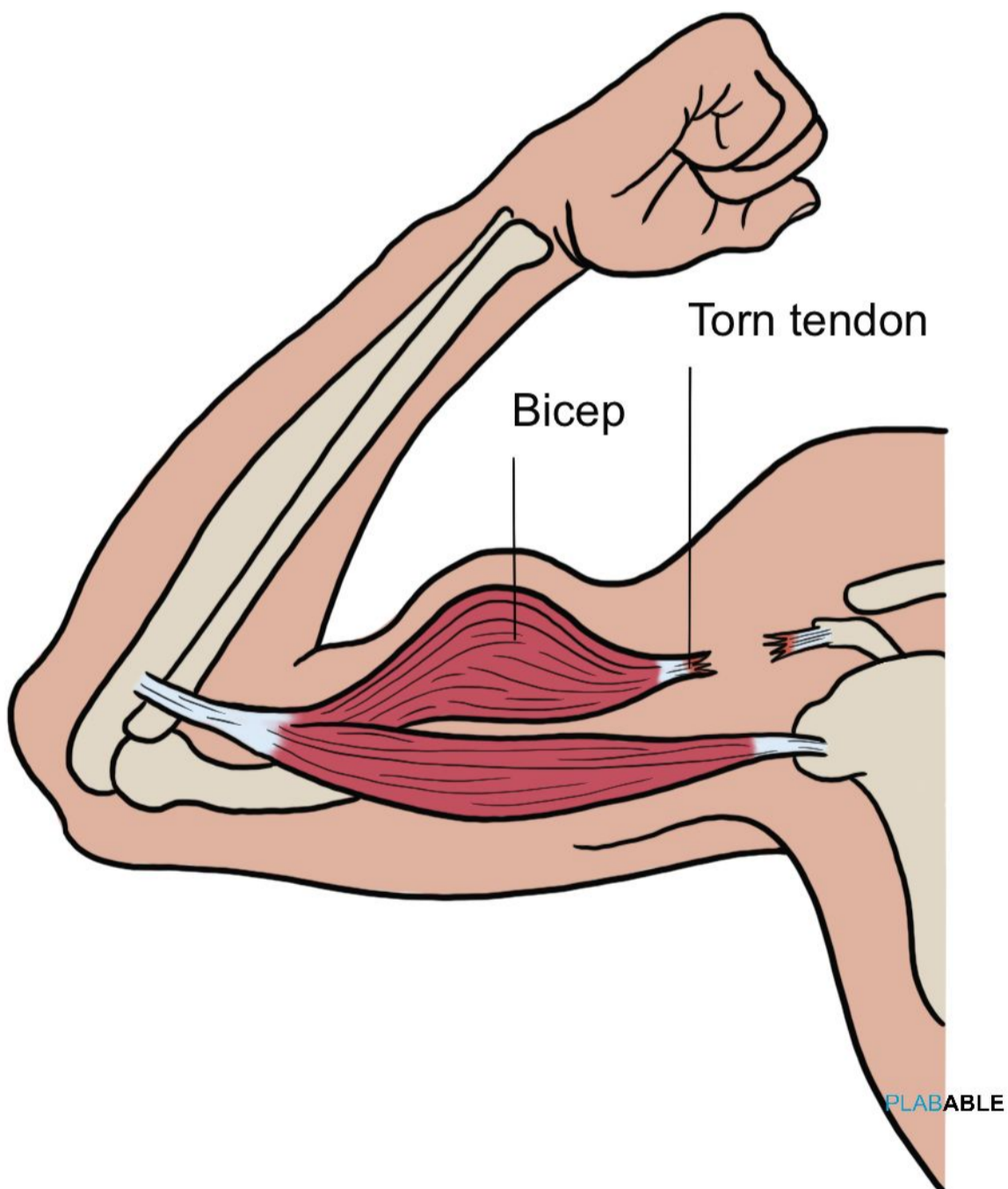
Cranial nerves

1. **Olfactory** : Smell
2. **Optic** : Pupillary light reflex
3. **Oculomotor** : Eye muscles, LR6,SO4,O3
4. **Trochlear** : SO4
5. **Trigeminal** : Afferent limb of corneal reflex,
Jaw deviation → Same side of the lesion
6. **Abducens** : LR6
7. **Facial** : **LMN** : Facial paralysis Upper +
Lower **UMN** : lower
facial paralysis only. + Taste
anterior $\frac{2}{3}$ of the tongue
8. **Vestibulocochlear** : Hearing and Balance
9. **Glossopharyngeal** : Taste posterior $\frac{1}{3}$ of the
tongue & gag reflex
10. **Vagus** : Motor innervation to soft palate,
pharynx, larynx, Sensory from viscera, weak
cough → Uvula deviation opposite side
11. **Accessory** : Trapezius &
sternocleidomastoid, dropped scapula
12. **Hypoglossal** : Tongue deviation same side of
lesion

Upper limb common injuries

Biceps rupture

- Proximal biceps = **Popeye sign**
- Distal biceps = Sharp pain in cubital fossa

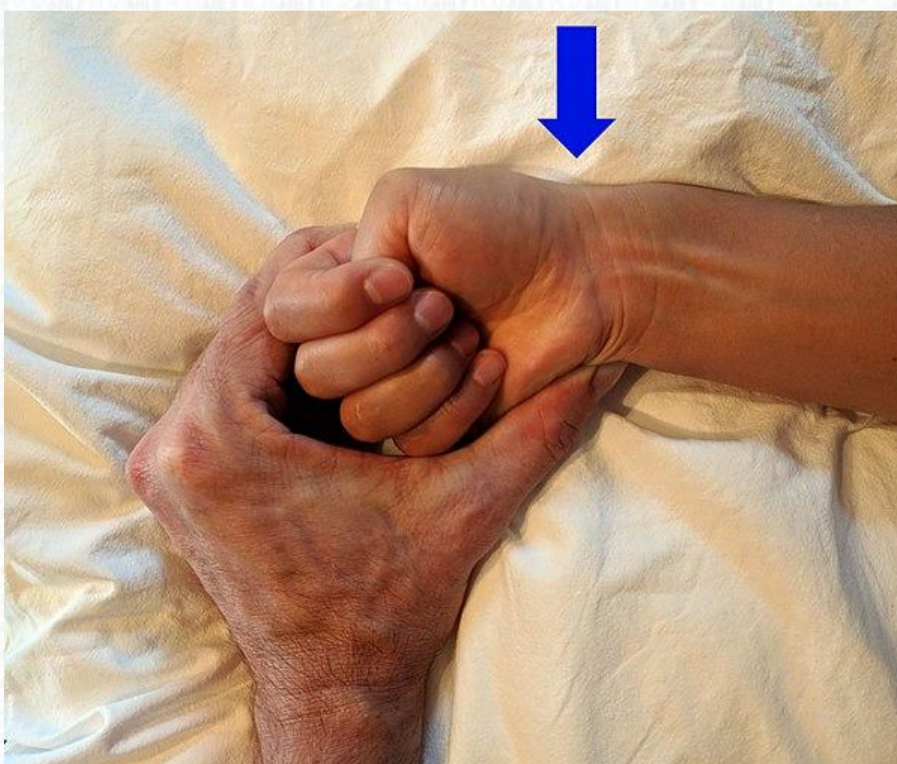
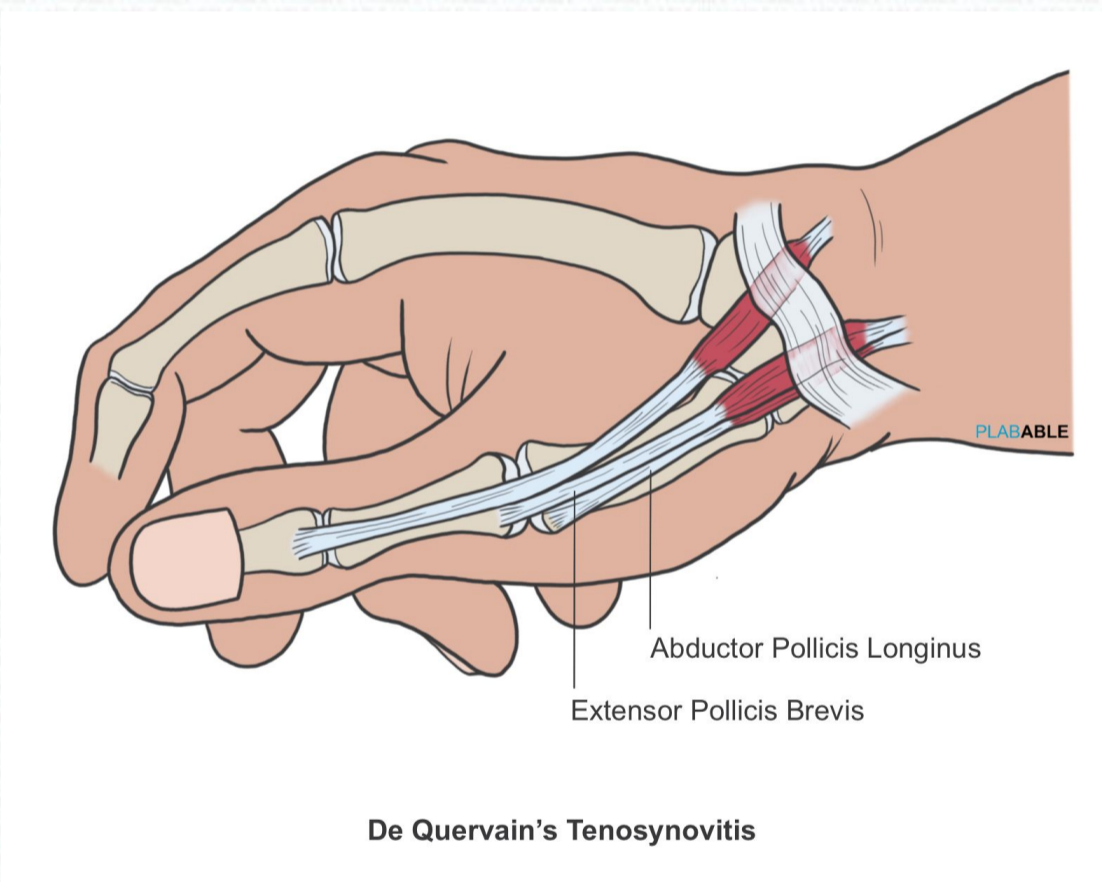


Popeye Muscle (Torn Proximal Bicep Muscles)

Upper limb common injuries

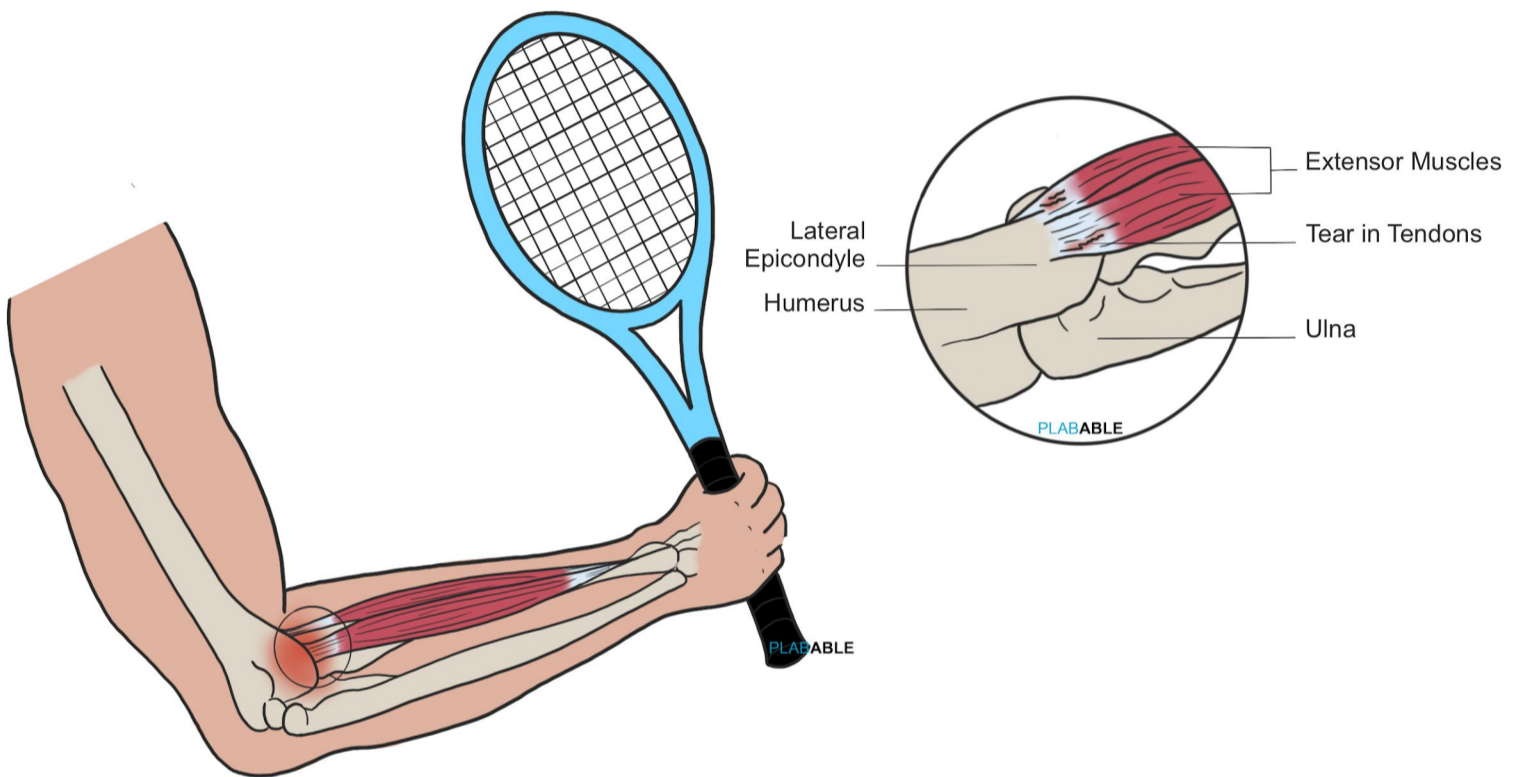
De Quervain tenosynovitis

- Inflammation of **extensor pollicis brevis** & **abductor pollicis longus**
- Repetitive strain injury
- Test: Finkelstein test




Upper limb common injuries

- **Tennis elbow** : Lateral epicondylitis
- **Golfers elbow** : Medial epicondylitis



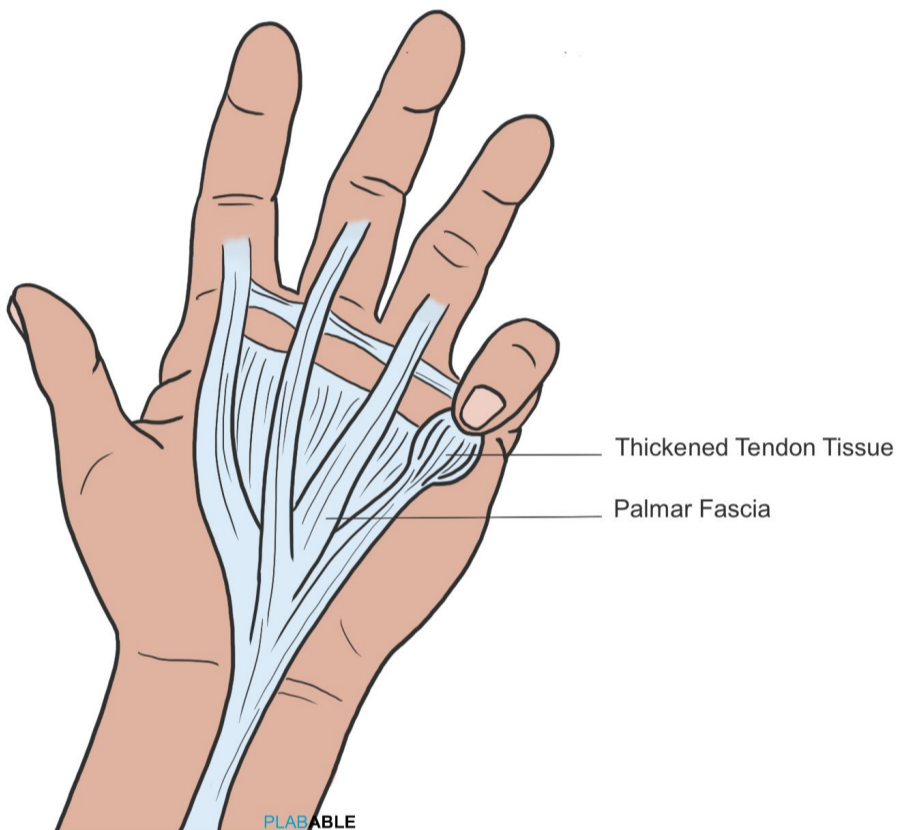
Tennis Elbow



LATERAL

Upper limb common injuries

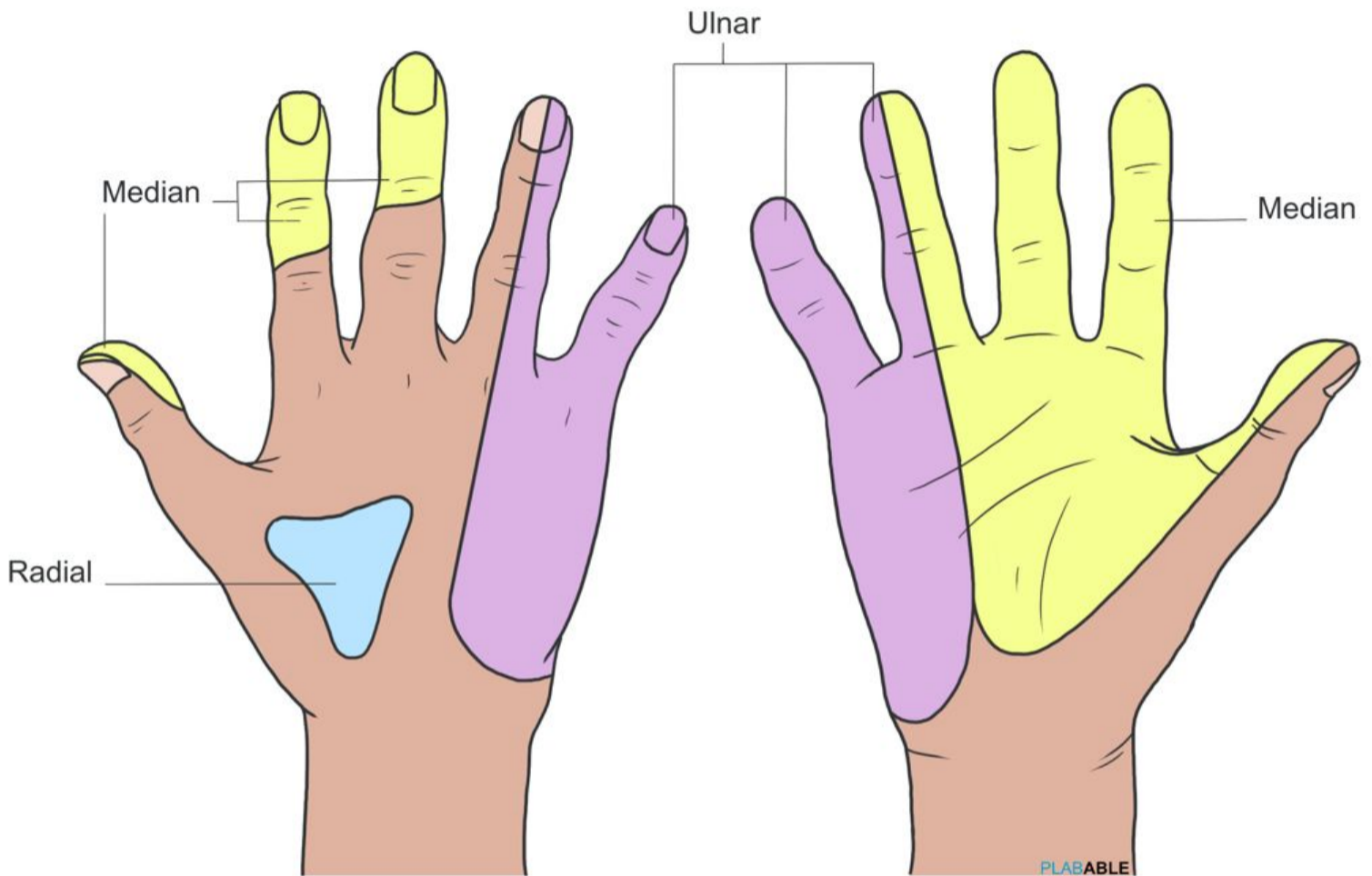
- **Dupuytren's contracture** : Thickened palmar fascia



Dupuytren's Contracture



Sensory distribution of hand



**Ulnar Nerve, Median Nerve, Radial Nerve
Sensory Distribution**

Clincher: Leg veins & nerves

	Vein	Nerve
Medial	Long (great) saphenous V	Saphenous N
Lateral	Short saphenous V	Sural N

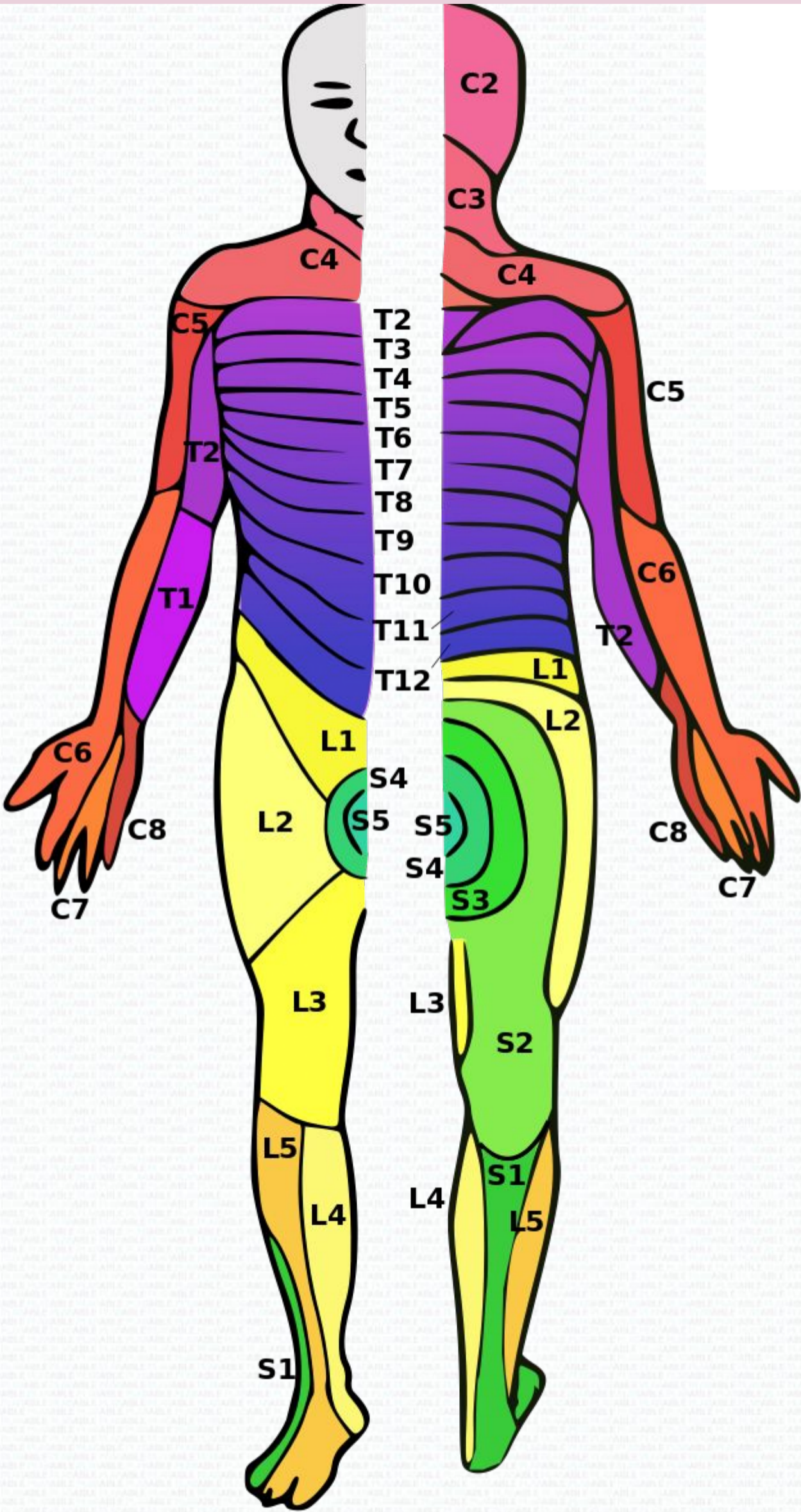
Motor innervation

- C5= Elbow flexors
- C6= Wrist extensors
- C7= Elbow extensors
- C8= Finger flexors
- T1= Finger abductors/adductors

- L2= Hip flexors
- L3= Knee extensors
- L4= Ankle dorsiflexors
- L5= Long toe extensors
- S1= Ankle plantar flexors

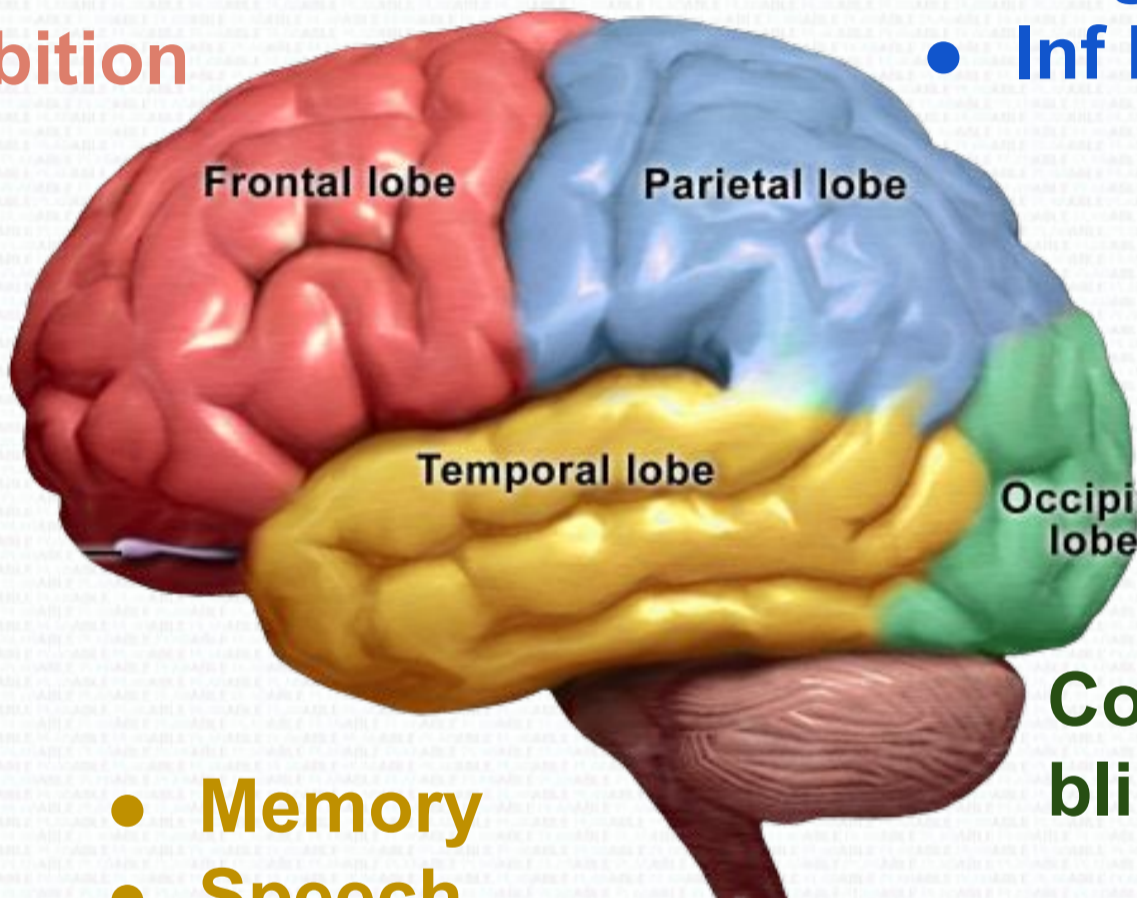
Do the innervation dance to remember

Sensory dermatomes



Lobe wise symptoms

Inhibition



- Inattention
- Neglect
- Inf H/Q

- Memory
- Speech
- Sup H/Q

Cortical blindness

Inf H/Q = Inferior hemi quadrantanopia

Sup H/Q = Superior hemi quadrantanopia

Thyroid

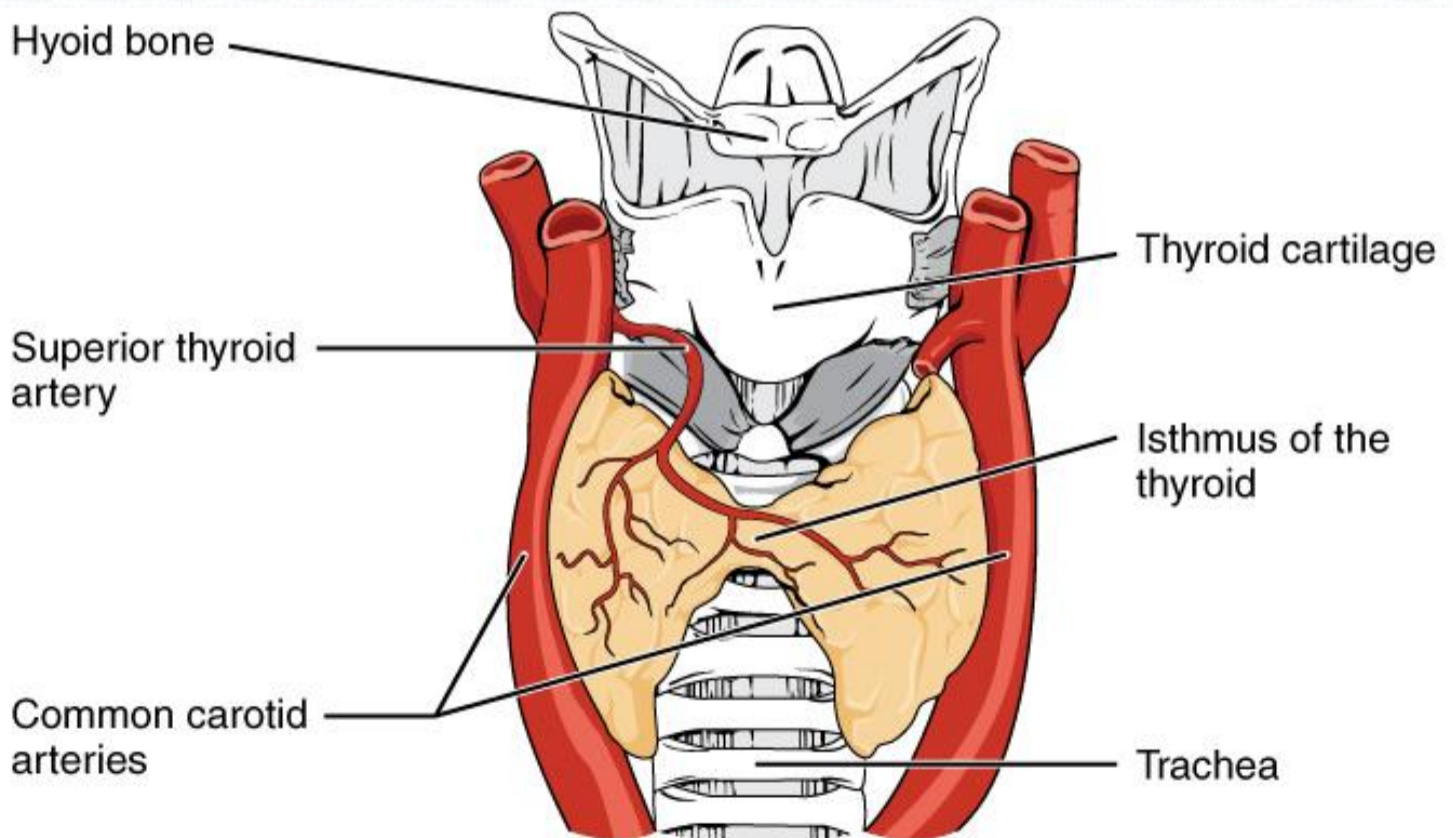
Nerve injury in thyroidectomy

Recurrent laryngeal nerve

- Unilateral : Hoarseness
- Bilateral : Aphonia

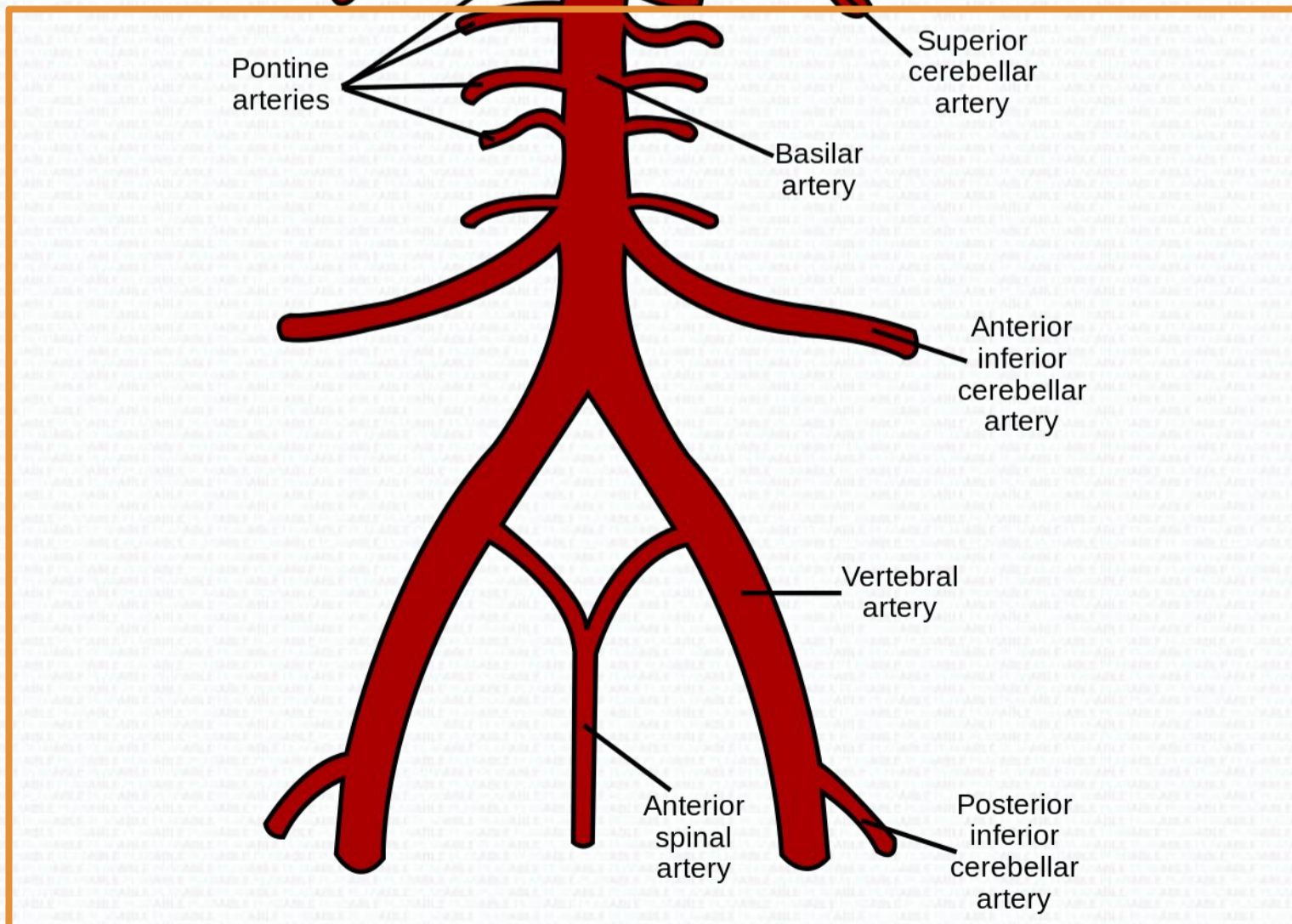
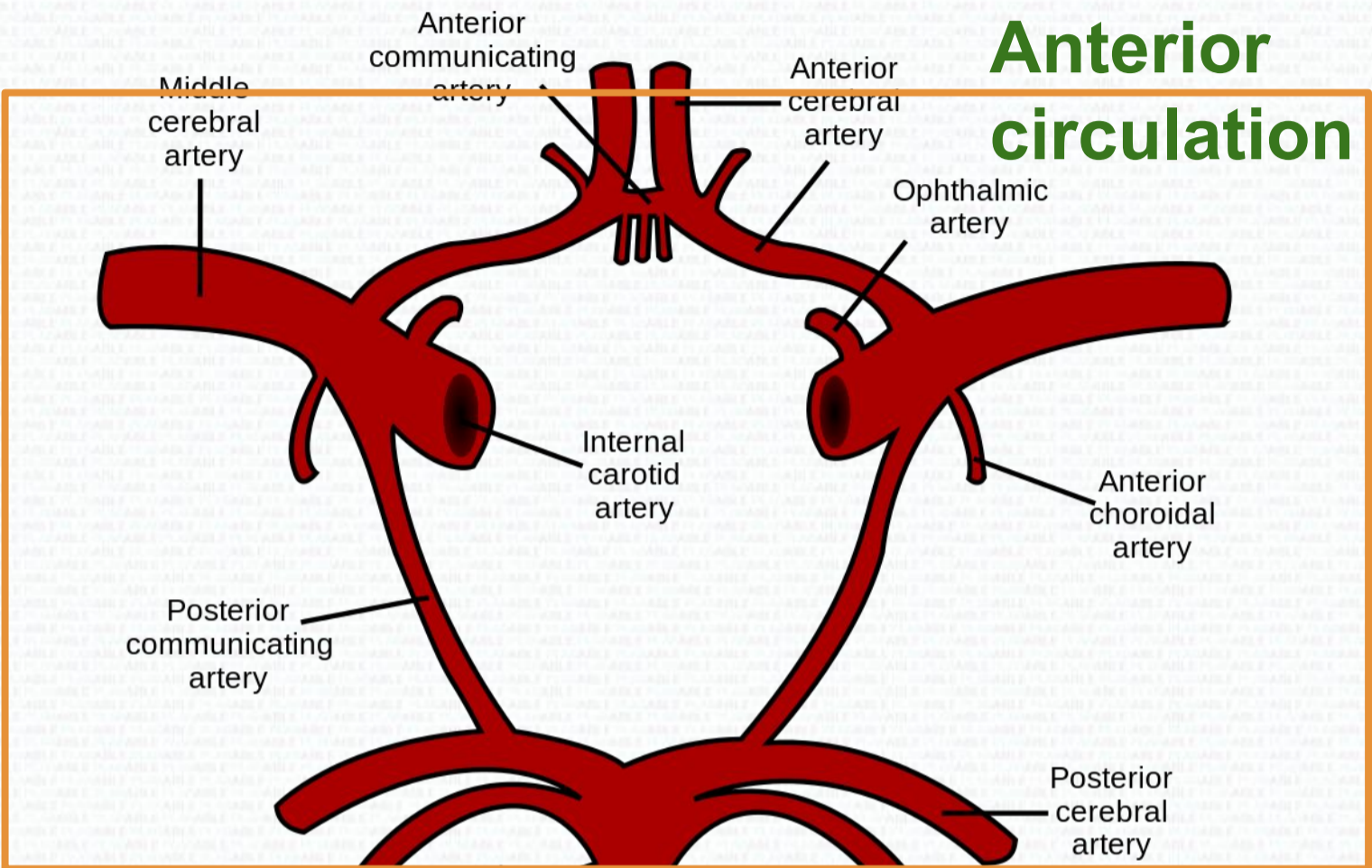
Superior laryngeal nerve : Decreased pitch

Blood supply



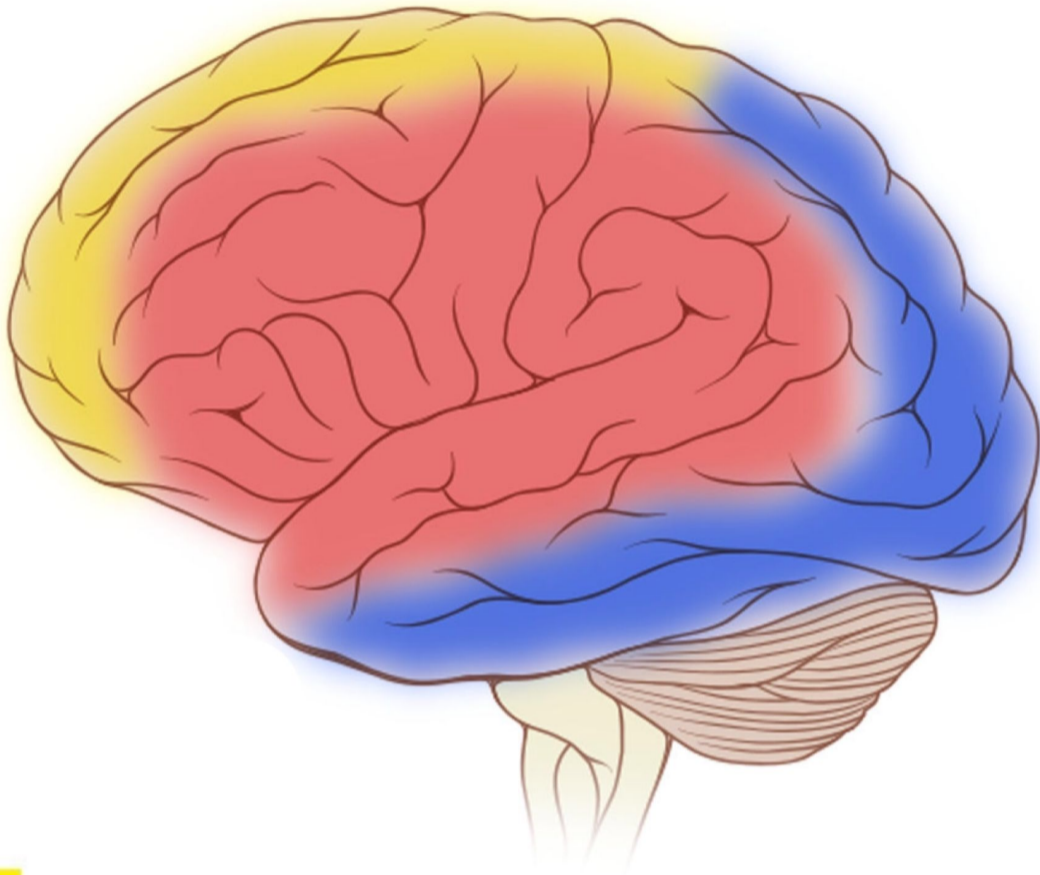
Circle of Willis

Anterior circulation



Posterior circulation

Blood supply



Anterior cerebral artery



Middle cerebral artery



Posterior cerebral artery

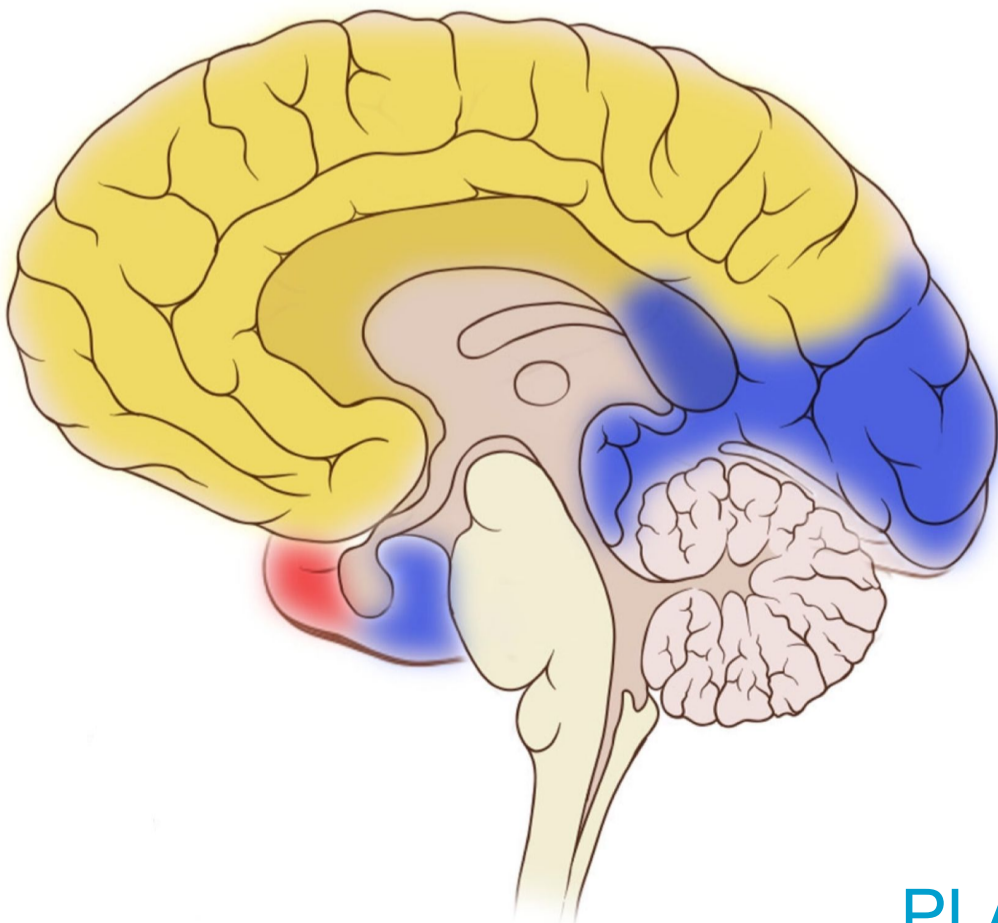


Image attributions

https://en.wikipedia.org/wiki/Transpyloric_plane#/media/File:Gray1225.png

H V Carter Public domain

https://en.wikipedia.org/wiki/Human_leg#/media/File:Human_leg_bones_labeled.svg

Jecowa Public domain

https://en.wikipedia.org/wiki/Winged_scapula#/media/File:Scapula_Winging_in_Long_Thoracic_Nerve_Palsy.jpg

Dwaipayanc CC BY SA 3.0

https://en.wikipedia.org/wiki/Hand#/media/File:Scheme_human_hand_bones-en.svg

Mariana Ruiz Public domain

https://en.wikipedia.org/wiki/Hand#/media/File:Scheme_human_hand_bones-en.svg

Mariana Ruiz Public domain

https://en.wikipedia.org/wiki/Biceps_tendon_rupture#/media/File:Dist._bizepssehnenruptur.jpg

Patenthalse Public domain

<https://en.wikipedia.org/wiki/Popeye#/media/File:Popyeye-logo.svg>

Elzie Crisler Segar Public domain

https://en.wikipedia.org/wiki/De_Quervain_syndrome#/media/File:Finkelstein_Test_Arrow.jpg

James Heliman, MD CC BY SA 4.0

https://en.wikipedia.org/wiki/Dupuytren%27s_contracture#/media/File:Morbus_dupuytren_fm.jpg

Frank C Müller, Baden-Baden CC BY SA 4.0

https://upload.wikimedia.org/wikipedia/commons/f/f0/Dermatoms_alt.svg

https://en.wikipedia.org/wiki/Lobes_of_the_brain#/media/File:Blausen_0111_BrainLobes.png

Blausen.com staff (2014) CC BY SA 3.0

https://en.wikipedia.org/wiki/Thyroid#/media/File:Anterior_thyroid.jpg

CFCF CC BY SA 3.0

https://en.wikipedia.org/wiki/Circle_of_Willis#/media/File:Circle_of_Willis_en.svg

Rhcastilhos Public domain

https://en.wikipedia.org/wiki/Cerebral_circulation#/media/File:Cerebral_vascular_territories_midline.jpg

Frank Gaillard CC BY 2.5

https://en.wikipedia.org/wiki/Cerebral_circulation#/media/File:Cerebral_vascular_territories.jpg

Frank Gaillard CC BY 2.5